

Laminitis

Of all the diseases suffered by the equine species, laminitis can be one of the most severe and debilitating afflictions encountered. Due to the serious nature of laminitis, it is a disease that must be treated immediately in order to help minimize damage to the feet. In some cases, laminitis can be so detrimental that the only humane course of action is to euthanize the affected animal. However, in most cases, with prompt and thorough care, laminitic horses can be successfully treated and returned to work over time. Because laminitis can be complicated by other factors, such as endocrine and metabolic disturbances, it is a disease that can require extensive management and the rehabilitation time can vary from weeks to months.

Laminitis, also known as founder, is a disease of the feet that can be caused by multiple factors including: grain overload acidosis, excessive intake of lush green grass, chronic obesity, acute abdominal pain, foot trauma, retained placentas, rhabdomyolysis, and endocrine disturbances such as hyperadrenocorticism (Cushing's disease) which affects horses middle aged and older. Although the causes of laminitis are varied, the end result is believed to be that trigger factors, which are currently unidentified, circulate throughout the animal's body and inadvertently activate the excessive production of matrix metalloproteinases (MMPs) in the lamellar tissue of the hoof. These MMPs are thought to be responsible for the lysis of the lamellar basement membrane. As the basement membrane disintegrates, the lamellar tissues, which hold the coffin bone in place, separate. Once the connection of the coffin bone to the hoof wall capsule is impaired, the coffin bone can either rotate or, in very severe situations, sink down through the sole of the foot.

This initial phase of laminitis, in which significant pathology occurs in the foot, is referred to as the developmental phase. Unfortunately, during this 8- 36 hour phase, there are no apparent signs of pain or heat in the foot, and as a result damage is incurred before the horse shows any signs of discomfort. Thus, by the time the horse is painful, the process of lamellar deterioration is already well underway. It is for this reason that immediate medical attention is needed to try to mitigate the damage in the feet before the situation becomes irreparable. Depending on the duration and severity of the laminitis, the outcome can range from a perfectly sound horse to one that sloughs its hoof capsules and must be euthanized. Other outcomes include rotation of the coffin bone, abscesses in the feet, white line disease, and chronic pain caused by instability and inflammation within the hoof capsule

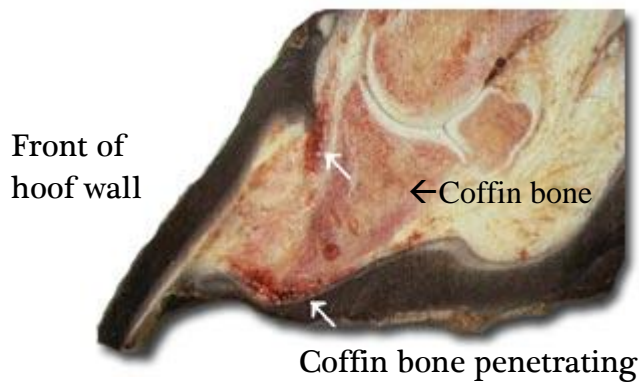
How do I know if my horse has laminitis?

After the developmental phase of laminitis is over, the horse enters the acute phase of laminitis and will show varying degrees of discomfort. It is during this phase that an astute observer can detect that a horse has laminitis. Horses with laminitis will often stand with their front legs extended forward and their hind legs tucked up under themselves in an attempt to shift their weight from their front feet (particularly the toe region) to their hind end. If a horse has laminitis in all four feet, a much less common occurrence, they will stand with their front feet extended back and their hind feet extended forward. Because of the pain in the laminae, these horses will resist movement, walking slowly and cautiously to avoid putting weight on their toes. When standing, one may see these horses continuously shift their weight from one front foot to the other – another manifestation of pain in the feet.

Characteristic stance
of a laminitic horse



During a physical exam performed by a veterinarian, the clinician will note that the feet are warmer than normal and that the digital pulse is either bounding (the acute phase of laminitis) or mild to moderately increased (the chronic phase of laminitis). The horse will be positive to hoof testers over the toe and sole region and sometimes over the cranial portion of the frog. Radiographs should be taken to evaluate the degree of lamellar separation in the foot, and to monitor changes in the position of the coffin bone. If the coffin bone perforates through the sole of the foot, euthanasia should be seriously considered. In cases where a horse has had chronically sore feet, other possible causes that must be ruled out before treating for laminitis are navicular disease, hoof abscesses, fractures of the coffin bone, corns, white line disease, poor trimming/shoeing and bruised soles.



Photograph of a laminitic hoof. You can see the rotation of the coffin bone in the hoof capsule and the coffin bone perforating the sole.

How do I treat my horse if it is diagnosed with laminitis?

Immediate treatment of laminitis is very important to stop the condition from becoming worse. If there is an underlying cause, such as too much green grass or Cushing's disease (an endocrine disease in which too much cortisol is released in the horse's system), this cause must be addressed if treatment is to be successful. After correcting the inciting problem, the pain/inflammation cycle must be controlled – this is usually done with the administration of phenylbutazone. Next, the horse's feet must be considered. Padding the feet with foam can help make the horse more comfortable and distribute the weight proportionately across the sole, thereby reducing the weight on the toe. The heels of the horse can also be elevated with plastic cuffs to decrease tension on the deep digital flexor tendon and to better align the coffin bone if it has started to rotate. Most importantly, though, the foot must be trimmed appropriately to decrease the amount of pull on the deep digital flexor tendon when the horse moves. Once the foot has healed, and the inflammation in the foot has resolved, shoes can be applied to help properly support the horse's coffin bone.

Further treatment options for laminitis, especially in the acute stage, include using vasodilators and antithrombogenic drugs to alter blood flow to the feet. If the horse is diagnosed with Cushing's disease, the drugs pergolide and cyproheptadine can be used to help control the laminitis often caused by this disease. Along with the various medications and shoeing changes, the horse should be kept confined in a stall until the feet have stabilized. Depending on the severity of the laminitis, the horse may be stall rested anywhere from a week to six months. It is recommended that the horse is not ridden or trailered for six months if there has been any rotation of the coffin bone. Intermittent radiographs should be taken to help monitor the course of the disease and its resolution.